

mmah_2020_IOP_Conf._Ser.__
Earth_Environ._Sci._575_01202
5.pdf
by

FILE	MMAH_2020_IOP_CONF._SER.__EARTH_ENVIRON._SCI._575_012025.PD F (472.71K)		
TIME SUBMITTED	14-NOV-2020 11:04PM (UTC+0700)	WORD COUNT	2359
SUBMISSION ID	1445943779	CHARACTER COUNT	12424

PAPER • OPEN ACCESS

Effects of sugar and honey on the formation of collagen fibers in incision wound of domestic cat (*Felis domestica*)

To cite this article: R Ummah *et al* 2020 ⁹ *IOP Conf. Ser.: Earth Environ. Sci.* **575** 012025

View the [article online](#) for updates and enhancements.

Effects of sugar and honey on the formation of collagen fibers in incision wound of domestic cat (*Felis domestica*)

R Ummah¹, W S Monica², D K Sari³, Y M Adikurniawan⁴ and M N Amir⁵

¹Veterinary Medicine Study Program, Hasanuddin University, Makassar, South Sulawesi, Indonesia

²Division of Veterinary Internal Medicine, Veterinary Medicine Study Program Hasanuddin University, Makassar, South Sulawesi, Indonesia

³Division of Veterinary Pathology, Veterinary Medicine Study Program, Hasanuddin University, Makassar, South Sulawesi, Indonesia

⁴Division of Veterinary Surgery and Radiology, Veterinary Medicine Study Program, Hasanuddin University, Makassar, South Sulawesi, Indonesia

⁵Faculty of Pharmacy, Hasanuddin University, Makassar, South Sulawesi, Indonesia

E-mail: waodesanta@gmail.com

Abstract. This study aimed to determine the effect and comparison of histopathological features of the skin of domestic cat (*Felis domestica*) on the formation of collagen fibers in the incise wound after treated by sugar and honey. Materials and methods in this study 15 male domestic cats were used in this study and were divided into five groups of Negative control group (KKN) without treatment, Positive control group (KKP) used Bioplacenton®, Group 1 (KP1) used sugar, Group 2 (KP2) used honey and Group 3 (KP3) used sugar and honey (combination) for 14 days, topically. The incision wound was made on the back of the domestic cat and the treatments were given daily for 14 days; the skin samples were taken on days 4, 9 and 14 to observe the formation of collagen fibers. The process of collagen fibers formation was observed and scoring was done from score 0 to +4 based on the density of collagen fibers in the wound area. Score changes data were analyzed descriptively. Results showed that KKN and KP2 collagen fibrous density was similar at day 4 score 0, day 9 score +1, and day 14 score +2. KP1 and KP3 collagen fibrous density were similar at day 4 score +1, day 9 score +2, and day 14 score +3. While KKP collagen fibrous density was high at day 4 score +1, day 9 score +3, and day 14 score +4. KP3 showed a good collagen fiber formation with the density was almost similar to the positive control group (KKP). The control groups (KKN and KKP) and the treatment groups (KP1, KP2 and KP3) showed differences in the formation of collagen fibers, fibroblast cells and the discovery of inflammatory cells on days 4, 9 and 14 during the wound healing process. The provision of sugar and honey in combination showed a good influence in the process of formation of collagen fibers during the wound healing process.

1. Introduction

The domestic cat is the cat evolution of wild cats that adapt to the environment near humans. As a beloved animal, cats require health care, such as wound care [1]. The wound is defined as the discontinuity of a tissue or the lost or damaged state of the body tissues. This damage can be caused by sharp-object trauma and blunt objects, changes in temperature, chemical substances, explosions,



Content from this work may be used under the terms of the [Creative Commons Attribution 3.0 licence](https://creativecommons.org/licenses/by/3.0/). Any further distribution of this work must maintain attribution to the author(s) and the title of the work, journal citation and DOI.

electric shock, or insect bites. Wounds are usually a lot to occur on the skin area [2]. One is caused by the wound of incision [3].

The incision wound is an open wound where the skin or membrane of the tissues is damaged; damage occurred due to deliberate (surgical operation) and accidental [4]. In the event of skin tissue, healing and cell regeneration occur automatically as the body's physiological response [5]. The main component in the wound healing process is collagen besides epithelial cells [6].

Collagen is mostly a type of protein in the human body and animals. Collagen is a fibers-shaped protein that is the main part of connective tissue that is needed in wound healing, the formation of scar tissue, and the formation of bone matrix [7]. The use of natural substances in wound healing can use sugar and honey. Sugar has antibacterial properties and helps improve wound healing and the development of granulation layers [8] while honey contains antibacterial substances, so it is good to treat burns and infectious diseases [9].

2. Materials and methods

This research was conducted in the Education Veterinary Clinic Pathology Laboratory of Hasanuddin University. The samples used in this study were 15 male domestic cats. The samples were divided into five groups, i.e., group 1 as the negative control group (KKN) without any treatment, group 2 as the positive control group (KKP) treated with Bioplacenton®, group 3 (KP1) treated with sugar, group 4 (KP2) treated with honey, and group 5 (KP3) treated with sugar and honey (combination). The number of samples used in this study was based on the formula of determining the large sample for experimental trials of the group's randomized design.

The animals were acclimated for seven days before being given treatment. Cats were then anesthetized using ketamine at a dose of 10 mg/kg BW (100 mg/mL) and xylazine at a dose of 2 mg/kg BW (20 mg/mL) intramuscularly (IM). After being anesthetized, a rectangular incision was made with a size of 2 cm × 1 cm. The sampling process was carried out on days 4, 9, and 14 after the cats were treated in each group. The final stage was histological preparations, consisted of several stages, fixation, trimming, processing, embedding, blocking, cutting, and staining with hematoxylin and eosin (HE staining).

3. Results and discussion

Histopathological scoring parameters for collagen density were presented in table 1.

Table 1. Collagen fiber density scores.

Groups	The 4 th day	The 9 th day	The 14 th day
KKN (Without treatment)	0	+1	+2
KKP (Bioplacenton®)	+1	+3	+4
KP 1 (Sugar)	+1	+2	+3
KP 2 (Honey)	0	+1	+2
KP 3 (Sugar + Honey)	+1	+2	+3

0 = No collagen fibers were found in the wound area

+1 = density of collagen fibers in the area of low wounds (less than 10% part visual field)

+2 = density of collagen fibers in the area of moderate injury (10-50% part visual field)

+3 = Density of collagen fibers in tightly wound areas (50-90% part visual field)

+4 = The density of collagen fibers in the wound area is very tight (90-100% part visual field)

Table 1 showed on the 14th day, negative control group (KKN) and group 2 (KP2) showed a density of collagen fibers in the area of moderate injury with a score of +2. Group 1 (KP1) and treatment group 3 (KP3) showed a density of tight collagen fibers with a score of +3. Whereas the positive control group (KKP) showed that the density of collagen fibers in the wound area was very tight with a score of +4. The treatment group that showed a good level of formation of collagen fiber density was group 1 (KP1) and group 3 (KP3) in combination (sugar and honey) almost same fibers

with the formation of collagen fiber density in the positive control group using Bioplacenton® with collagen fiber density the wound area is very tight. ⁵

Collagen is an extracellular matrix protein that plays a role in the formation of scars in the healing phase of connective tissue. The high density of collagen in the proliferation phase is a sign of a faster wound healing process [10]. Sugar can secrete TGF- α , attract macrophages to wound tissue and express integrin α and β receptors that function in fibroblast proliferation [10]. Fibroblasts are the main element in the repair process for the formation of structural proteins that play a role in tissue formation. Fibroblasts originate from undifferentiated mesenchymal cells, producing mucopolysaccharides, amino acids glycine, and proline, which are the basic ingredients of collagen fibers that will link wounds [11,12]. Honey contains amino acids useful for the growth of synthesis of other materials and energy sources, for example, for the synthesis of structural proteins such as collagen [13]. Sugar and honey have a role in collagen synthesis so that it can accelerate the process of wound healing. The combination of working sugar and honey in group 3 (KP3) shows a better recovery process than the single use of sugar in group 1 (KP1) or honey in group 2 (KP2).

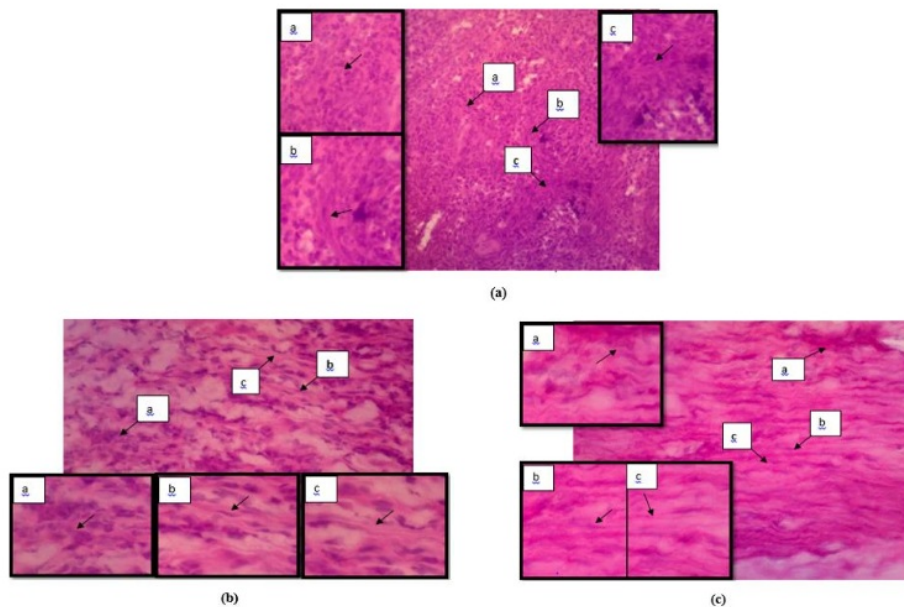


Figure 1. Histopathological features of cat skin in group 3 (KP 3) used sugar and honey of the (a) 4th day, (b) 9th day and (c) 14th day. (a) inflammatory cells, (b) fibroblasts cells and (c) collagen fibers (HE staining, 40 \times 10 magnification).

Group 3 (KP3) on the 4th day, showed inflammatory cell infiltration, the presence of proliferation of fibroblasts with moderate density and density of collagen fibers in the area of low wounds (less than 10% part field of view) (figure 1a). Sugar and honey have hygroscopic properties, which draw water from the surrounding environment. Thus creating high osmotic pressure and being able to attract macrophages to the wound area. Macrophages will secrete various kinds of cytokines and growth factors needed in wound healing. The cytokines secreted in platelet cells also function to secrete inflammatory factors and release various potential growth factors such as Transforming Growth Factor- β (TGF- β), Platelet-Derived Growth Factor (PDGF), Interleukin-1 (IL-1), Insulin-like Growth Factor-1 (IGF-1), Epidermal Growth Factor (EGF), and Vascular Endothelial Growth Factor (VEGF), cytokines and chemokines. This mediator is needed in wound healing to trigger cell healing,

differentiation, and initiate the recovery of damaged tissue [14]. On the 9th day, the histopathological examination showed the infiltration of inflammatory cells with low density. The occurrence of fibroblast proliferation and density of collagen fibers in the area of moderate injury (10 to 50% part field of view) (figure 1b). On the 14th day, it showed a small number of inflammatory cells, fibroblast cells, and density of collagen fibers in tightly wound areas (50 to 90% part field of view) (figure 1c). Honey has a relatively acidic pH level, ranging from 3.2 to 4.5, to prevent bacterial growth. Honey has a collagenic effect that is acetylcholine, which can improve blood circulation and increase circulation, which can meet the needs of oxygenation and nutrition in the injured area. Oxygen plays an essential role in the formation of collagen. The condition can complement the lack of sugar in wound healing, thereby accelerating the process of epitomization and angiogenesis [13,15].

4. Conclusion

The provision of sugar and honey affected the formation of collagen fibers in the healing of domestic cat (*Felis domestica*) incision wounds. Wound healing using the provision of sugar and honey in combination gave a good influence in the process of formation of collagen fibers, which was not much different from the formation of a collagen fibrous density in the group treated with Bioplacenton®.

Reference

- [1] Sulaiman 2010 *Bisnis Pembibitan Kucing -Dari Hobi Jadi Uang* (Yogyakarta: Lily Publisher)
- [2] Angel P G, Kalangi S and Wangko S 2014 *Gambaran Proses Radang Luka Postmortem pada Hewan Coba [Skripsi]* (Manado: Universitas Sam Ratulangi)
- [3] Murti D A, Salim M N and Sabri M 2017 Efektifitas salep getah jarak pagar (*Jatropha curcas* L) pada fase epitelisasi penyembuhan luka sayat kulit mencit (*Mus musculus*) dengan pewarnaan masson trichrome *J. Ilm. Mhs. Vet.* **1** 465–72
- [4] Masrur A 2011 *Pengaruh Pemberian Kombinasi Salep Ekstrak Kulit Buah Naga (*Hylocereus polyrhizus*) dan Daging Lidah Buaya (*Aloe vera*) Terhadap Ekspresi Interlukin 6 (IL-6) dan Jumlah Sel Neutrofil pada Proses Penyembuhan Luka Insisi Tikus Putih (*Rattus norvegicus*) [Skri]* (Malang: Universitas Brawijaya)
- [5] Ferdinandez M K, Dada I K A and Damriyasa I M 2013 Bioaktivitas ekstrak daun tapak dara (*Catharantus roseus*) terhadap kecepatan angiogenesis dalam proses penyembuhan luka pada tikus wistar *Indones. Med. Veterinus* **2** 180–90
- [6] Perdanakusuma D S 2007 *Anatomi Fisiologi Kulit dan Penyembuhan Luka* (Surabaya: Airlangga University School of Medicine)
- [7] Rizka A, Budipramana V S and Fauziah D 2013 Kepadatan Kolagen tipe 1 pada luka operasi tikus Wistar yang mengalami anemia karena perdarahan akut *Media J. Emerg.* **2**
- [8] Ford R B and Elisa M M 2012 *Kirk and Bistner's Handbook of Veterinary Procedures and Emergency Treatment* (United States: Saunders Elsevier)
- [9] Puspaseruni K 2017 *Pengaruh Frekuensi Pemberian Madu Hutan Terhadap Kecepatan Kontraksi Luka Bakar Derajat Iia pada Kulit Tikus Putih (*Rattus novergicus*) Strain Wistar [Thesis]* (Malang: University Of Muhammadiyah Malang)
- [10] Isrofah, Seragih and Afandi M 2015 Efektivitas salap ekstrak daun binahong (*Anredera cordifolia* (ten) steenis) terhadap proses penyembuhan luka bakar derajat 2 termal pada tikus putih (*Rattus novergicus*) *Indones. J. Nurs. Pract.* **2** 27–39
- [11] Nur N N 2017 *Perbedaan Penyembuhan Luka Sayat Secara Makroskopis antara Pemberian Topikal Ekstrak Sel Punca Mesenkimal Tali Pusat Manusia dengan Gel Bioplacenton® pada Tikusputih Jantan (*Rattus norvegicus*) Galur Sprague Dawley [Skripsi]* (Bandar Lampung: Universitas Lampung)
- [12] Triyono B 2005 *Perbedaan Tampilan Kolagen disekitar Luka Insisi pada Tikus Wistar yang diberi Infiltrasi Penghilang Nyeri Levobupivakain* (Semarang: Universitas Diponegoro)
- [13] Zakariya M, Sudiana I and Wahyuni E D 2009 Efektifitas perawatan luka insisi dengan madu dan Povidon iodine 10% *J. Ners* **4** 1–8

- [14] Primadina N, Basori A and Perdanakusuma D 2019 Proses penyembuhan luka ditinjau dari aspek mekanisme seluler dan molekuler *Qanun Med. - Med. J. Fac. Med. Muhammadiyah Surabaya* **3** 31
- [15] Rostita 2007 *Berkat Madu: Sehat, Cantik dan Penuh Vitalitas* (Bandung: Qanita PT Mizan Pustaka)

ORIGINALITY REPORT

% **14**
SIMILARITY INDEX

% **9**
INTERNET SOURCES

% **3**
PUBLICATIONS

% **8**
STUDENT PAPERS

PRIMARY SOURCES

1 www.pmrslab.cn Internet Source % **6**

2 Submitted to Padjadjaran University Student Paper % **3**

3 journal.um-surabaya.ac.id Internet Source % **1**

4 Submitted to Uttarakhand Technical university Dehradun Student Paper % **1**

5 worldwidescience.org Internet Source % **1**

6 H F Zhao. "Anti-monocyte chemoattractant protein 1 gene therapy attenuates experimental chronic pancreatitis induced by dibutyltin dichloride in rats", Gut, 2005 Publication % **1**

7 repository.uinjkt.ac.id Internet Source % **1**

8

Internet Source

<% 1

9

iopscience.iop.org

Internet Source

<% 1

EXCLUDE QUOTES ON

EXCLUDE
BIBLIOGRAPHY ON

EXCLUDE MATCHES < 5
WORDS